



Theses and Dissertations

2011-04-04

Longitudinal Changes in the Corpus Callosum Following Pediatric Traumatic Brain Injury as Assessed by Volumetric MRI and Diffusion Tensor Imaging

Trevor Chuang Kuo Wu
Brigham Young University - Provo

Follow this and additional works at: <https://scholarsarchive.byu.edu/etd>



Part of the [Psychology Commons](#)

BYU ScholarsArchive Citation

Wu, Trevor Chuang Kuo, "Longitudinal Changes in the Corpus Callosum Following Pediatric Traumatic Brain Injury as Assessed by Volumetric MRI and Diffusion Tensor Imaging" (2011). *Theses and Dissertations*. 2996.

<https://scholarsarchive.byu.edu/etd/2996>

This Dissertation is brought to you for free and open access by BYU ScholarsArchive. It has been accepted for inclusion in Theses and Dissertations by an authorized administrator of BYU ScholarsArchive. For more information, please contact scholarsarchive@byu.edu, ellen_amatangelo@byu.edu.

Longitudinal Changes In The Corpus Callosum Following
Pediatric Traumatic Brain Injury

Trevor C. Wu

A dissertation submitted to the faculty of
Brigham Young University
in partial fulfillment of the requirements for the degree of
Doctor of Philosophy

Erin D. Bigler, PhD, Chair
Ramona Hopkins, PhD
Elisabeth Wilde, PhD
Dawson Hedges, MD
Michael Larson, PhD

Department of Psychology
Brigham Young University
August 2011

Copyright © 2010 Journal of Developmental Neuroscience

All Rights Reserved

ABSTRACT

Longitudinal Changes In The Corpus Callosum Following Pediatric Traumatic Brain Injury

Trevor C. Wu

Department of Psychology

Doctor of Philosophy

Atrophy of the corpus callosum (CC) is a documented consequence of moderate-to-severe traumatic brain injury (TBI), which has been expressed as volume loss using quantitative magnetic resonance imaging (MRI). Other advanced imaging modalities such as diffusion tensor imaging (DTI) have also detected white matter microstructural alteration following TBI in the CC. The manner and degree to which macrostructural changes such as volume and microstructural changes develop over time following pediatric TBI and their relation to a measure of processing speed is the focus of this longitudinal investigation. As such, DTI and volumetric changes of the CC in participants with TBI and a comparison group at approximately three and 18 months post injury and their relation to processing speed were determined.

Keywords: corpus callosum, pediatrics traumatic brain injury, diffusion tensor imaging

ACKNOWLEDGMENTS

The completion of my doctoral dissertation was realized through the tremendous support and mentoring of Dr. Erin D. Bigler (committee chair) and Dr. Elisabeth A. Wilde of Baylor College of Medicine and other committee members. This research project was supported by Grant NS-21889 awarded to Dr. Harvey S. Levin of Baylor College of Medicine by the National Institutes of Health. I would also like to acknowledge the generous technical support from Tracy J. Abildskov. I express my gratitude to the patients and their families for their involvement of this study. The past 4 years have been a rewarding journey both academically and spiritually. I would not have been able to accomplish it without the help and support of my family, especially my wife. This dissertation has been accepted for publication by the International Journal of Developmental Neuroscience. This is the pre-published version.

Table of Contents

Introduction.....	1
Neuropathology Associated with TBI	1
Diffusion Tensor Imaging.....	2
Microstructural Alterations Following TBI.....	3
Hypothesis.....	4
Method	5
Participants.....	5
Imaging	7
DTI Acquisition	7
Volumetric Acquisition.....	7
DTI Analysis.....	7
Intra-rater and Inter-rater Reliability	8
Volumetric Analysis	8
Cognitive Measure	9
Data Analysis	10
Results.....	11
Demographic and Injury Characteristics	11
Group Differences at three and 18 Months Post-Injury for DTI	12
Longitudinal DTI Analyses.....	16
Relation of DTI to Cognitive Functioning.....	17
Group Differences at three and 18 Months Post-Injury for Volumetrics	18
Longitudinal Volumetric Analyses	19

Relation of Volume to Cognitive Function.....	21
Discussion.....	21
Strengths, Limitations, and Future Directions	26
Conclusions.....	27
References.....	28

List of Tables

Table 1	Demographic and Injury Characteristics of TBI and OI Groups	13
Table 2	Group Difference of the CC for FA at 3 Months and 18 Months.....	14
Table 3	Group Difference of the CC for ADC at 3 Months and 18 Months	15
Table 4	Volumetric Differences in Corpus Callosum Sub-regions at 3 and 18 Months .	20

List of Figures

- Figure 1 Bar graphs with error bars illustrating the longitudinal change between three and 18 months post-injury in FA (a) and ADC (b) as measured by quantitative DTI tractography, and volume (c) as measured by volumetric analysis in the splenium/posterior sub-region of the CC in both the TBI and OI groups16
- Figure 2 Scatterplots with regression lines demonstrating the relation between Flanker baseline condition RT and FA of the splenium/posterior sub-region (a) and the total CC (b) at 18 months post-injury in the TBI and OI groups18
- Figure 3 T1-weighted sagittal images of a 16 year old male adolescent with orthopedic injury at three months (a) and 18 months (b) post-injury. T1-weighted images of a 15-year old male adolescent with moderate TBI (Glasgow Coma Scale score of 9) at three months (c) and 18 months (d) post injury is also presented24

Longitudinal Changes In The Corpus Callosum Following Pediatric Traumatic Brain Injury

Traumatic brain injury (TBI) is a major public health concern. According to Langlois and colleagues (Langlois, Rutland-Brown, & Thomas, 2005), approximately 475,000 children are treated for TBI annually in the United States, with the highest rate of hospitalization in the adolescent age range (129/100,000). Closed head trauma arising from falls and motor vehicle crashes is the most frequent cause of unintentional pediatric TBI, while penetrating brain injury accounts for less than five percent of TBI in the pediatric population. Children and adolescents are particularly vulnerable to closed head trauma (Thurman, Coronado, & Selassie, 2007), and TBI sustained at this critical developmental stage can have a profound negative impact on learning, behavior and psychological outcome (Yuan, et al., 2007).

Neuropathology associated with TBI

The neuropathology associated with TBI has been traditionally classified as either focal or diffuse injury. Focal injury, such as cerebral contusions or intracranial hemorrhage, can be readily identified on computed tomography (CT) or magnetic resonance imaging (MRI) (Benson, et al., 2007; Povlishock & Katz, 2005; Smith, Meaney, & Shull, 2003). In contrast, diffuse injury is usually less evident on conventional imaging. Recent studies have demonstrated the sensitivity and utility of diffusion tensor imaging (DTI) in identifying and characterizing microstructural pathologies, including those occurring from TBI (Alexander, Lee, Lazar, & Field, 2007; Arfanakis, et al., 2002; Ashwal, Holshouser, & Tong, 2006; Chu, et al., 2010; Ewing-Cobbs, Hasan, Prasad, Kramer, & Bachevalier, 2006; Mayer, et al., 2010; Nakayama, et al., 2006; Rugg-Gunn, Symms, Barker, Greenwood, & Duncan, 2001;

Salmond, et al., 2006; Wilde, et al., 2006; Wilde, et al., 2008; Wu, et al., 2010; Xu, Rasmussen, Lagopoulos, & Haberg, 2007).

Diffusion Tensor Imaging

Diffusion tensor imaging is based on two theoretical assumptions: water molecules in the brain are constantly moving, and the directionality and magnitude of diffusivities of water molecules are indicative of the integrity of underlying neuronal structures (Alexander, et al., 2007; Mori & Zhang, 2006; Mukherjee, Berman, Chung, Hess, & Henry, 2008). Healthy axonal membranes constrain water molecules intracellularly and are closely compacted in tracts minimizing free water in extracellular spaces as well (Yamada, Sakai, Akazawa, Yuen, & T., 2009). The DTI technique capitalizes upon this combination of constraining water diffusivity within and around the axon where aggregate white matter tracts can be inferred by linking similar characteristics of water diffusivity (Yamada, et al., 2009). This also means that when an axon is damaged water diffusion is altered which can be detected by various DTI metrics, including fractional anisotropy (FA) and apparent diffusion coefficient (ADC). FA measures the degree to which diffusion occurs in one particular direction, and is indicated by a coefficient ranging from 0 to 1, where 0 is completely random and 1 is maximally anisotropic. ADC reflects the overall magnitude of diffusivity. A small ADC represents greater constrained diffusivity. Neuronal swelling, cytoskeleton, or alterations of extracellular space secondary to injury and edema, often seen immediately following mild TBI, have been shown to disrupt normal diffusivities, resulting in increased FA and decreased ADC (Bazarian, et al., 2007; Chu, et al., 2010; Mayer, et al., 2010; Wilde, et al., 2008; Wu, et al., 2010). It is not clear whether the initial increase in FA is limited to mild TBI or whether this finding reflects the feasibility of performing DTI during the subacute

phase of mild injury. In contrast, during axonal degeneration following TBI, water diffusivity increases, which reduces FA and increases ADC (Alexander, et al., 2007; Assaf, Beit-Yannai, Shohami, Berman, & Chohen, 1997; Belanger, Vanderploeg, Curtiss, & Warden, 2007; Benson, et al., 2007; Ducreus, et al., 2005; Newcombe, et al., 2007; Povlishock & Katz, 2005; Sidaros, et al., 2008; Wilde, et al., 2008; Xu, et al., 2007), which relates to histologically identified axonal pathology (Mac Donald, Dikranian, Bayly, Holtzman, & Brody, 2007; Mac Donald, Dikranian, Song, et al., 2007; S. Wang, et al., 2009).

Microstructural Alterations Following TBI

Following TBI, several axonal pathways have robustly demonstrated altered diffusivities including the corpus callosum (CC), anterior limb of the internal capsule, cingulum bundles, uncinate fasciculi, centrum semiovale, thalamic white matter projections and inferior and superior longitudinal fascicule though results vary across ages, amount of time post-injury and severities of injury (Arfanakis, et al., 2002; Babikian, et al., 2010; Bendlin, et al., 2008; Huisman, et al., 2004; Inglese, et al., 2005; Kumar, et al., 2010; Levin, et al., 2008; Little, et al., 2010; Nakayama, et al., 2006; Niogi, et al., 2008; Ptak, et al., 2003; Rugg-Gunn, et al., 2001; Sidaros, et al., 2008; J. Wang, Bakhadirov, Devous, Adbdi, & McColl, 2008; Wilde, et al., 2006; Wilde, et al., 2008; Xu, et al., 2007). Among these pathways, the CC is selectively vulnerable where callosal damage is common in children and adolescents with TBI (Beauchamp, et al., 2009; Ewing-Cobbs, et al., 2008). The long coursing nature and the midline location adjacent to the falx cerebri make CC particularly susceptible to the traumatic axonal injury (TAI) resulting from shear-strain forces.

Decreased FA and increased ADC (Bendlin, et al., 2008; Ewing-Cobbs, et al., 2008; Gorrie, Dufrou, Brown, Gibson, & Waite, 2001; Kraus, et al., 2007; Levin, et al., 2008; Wilde, et al.,

2006), and volumetric reduction (Anderson & Bigler, 1994; Benavidez, et al., 1999; Kim, et al., 2008; Levin, et al., 1990; Tomaiuolo, et al., 2004; Wilde, et al., 2006) in the CC following TBI are consistently documented in children and adolescents during the subacute to chronic stage. However, to date, no study has systematically examined how volumetric changes in the CC relate to changes in DTI metrics in a longitudinal design.

Given the widespread interhemispheric connections that course through the CC and its primary function in mediating interhemispheric communication (Pannek, et al., 2010), callosal pathway disruptions can have a profound impact on cognitive functioning, including the speed of information processing (Aukema, et al., 2009; Biegon, Eberling, & Richardson, 1994; Chepuri, et al., 2002; Jokinen, Ryberg, & Halska, 2007; Turken, et al., 2008). Patients with TBI often demonstrate slowed information processing on neuropsychological testing (Battistone, Woltz, & Clark, 2008; Johansson, Berglund, & Ronnback, 2009; Madigan, DeLuca, Diamond, Tramontano, & Averiall, 2000). In a previous cross-sectional study, we have found a significant relation between speed of processing and CC integrity as measured by DTI FA in children and adolescents with TBI at three months post-injury (H. S. Levin, et al., 2008).

Hypothesis

In the present study, we examined longitudinal changes in the CC volume and microstructural integrity from three to 18 months post injury in a group of children and adolescents with complicated mild and moderate to severe TBI and a comparison group of children and adolescents with orthopedic injury (OI), and the relation between these imaging findings and speed of information processing. We hypothesized that the OI group would have higher FA and lower ADC in the total CC and its sub-regions (genu/anterior,

body/central and splenium/posterior) at three months post injury and these differences would become more pronounced at 18 months as a result of either the disruption of a normal developmental trajectory or continued degeneration. We anticipated that the TBI group would demonstrate slower cognitive processing speed than the OI group.

Method

Participants

This study was approved by the Institutional Review Board of all institutions from which data were collected. Informed consent was obtained from each participant or his/her legal guardian as appropriate. All participants were recruited from consecutive admissions to emergency rooms at Level-1 trauma centers in Houston, Dallas, and Miami. All participants were fluent in English and were between the ages of seven and 17 years at the time of study enrollment. As part of the study design, magnetic resonance imaging (MRI) and cognitive assessments were planned for three and 18 months post-injury.

The TBI group was comprised of 23 participants (15 males and 8 females) between the ages of 7.8 and 17.2 years ($M = 12.9 \pm 3.2$) who sustained either complicated mild or moderate-to-severe TBI. The severity of the injury was determined by the postresuscitation Glasgow Coma Scale (GCS) scores (Teasdale & Jennett, 1974). Severe TBI was defined as a GCS score of 3 – 8, and moderate TBI as 9 – 12. A complicated mild TBI was defined as a GCS score of 13 – 15 with acute (within 24 hours post-injury) trauma-related CT findings (e.g., contusions and hematomas). Participants with complicated mild TBI were recruited because the presence of cerebral lesions is predictive of poor cognitive outcome at 12 month post-injury (Levin, et al., 2008). Given these classifications, there were 16 severe, 4 moderate and three complicated mild cases. Other eligibility criteria included Abbreviated

Injury Scale (AIS) (Committee on Injury Scaling, 1998) score of < 4 for body parts other than the head and an Injury Severity Scale ISS score of < 12 . The modal mechanisms of injury were motor-vehicle or motorcycle crashes. All but one TBI participants were right-hand dominant.

The OI group included 25 participants (18 males and 7 females), ages ranging 7.1 – 16.3 years ($M 11.8 \pm 2.7$) who were hospitalized overnight, generally for upper or lower extremity bone fractures. The OI comparison group controls for risk factors that predispose individuals to injury, including pre-existing behavioral problems, subtle learning disabilities, and family variables. The absence of significant previous head trauma in the OI group was confirmed through a detailed developmental questionnaire administered to the parent or legal guardian, and the absence of concurrent head injury was confirmed through medical records and/or physician report of relevant history and physical examination findings and, when available, clinical imaging results (i.e., negative CT). OI in this cohort primarily resulted from sports and play-related injuries and falls. All but four controls were right-hand dominant.

Potential participants in both groups were excluded if there was evidence of previous head injury, child abuse, pre-existing neurologic disorders (e.g., cerebral palsy, mental retardation, and epilepsy) or diagnosed learning disabilities, pre-existing severe psychiatric disorders (e.g., schizophrenia, or pervasive developmental disorders), prematurity or low birth weight (birth weight < 2500 grams and gestation < 37 weeks), penetrating gunshot wounds to the brain, contraindication to undergoing MRI, hypoxia ($PO_2 < 96$ mmHg for age 6 – 16 years) or hypotension (systolic blood pressure 2 standard deviations below the mean for the age group).

Imaging

All participants underwent MRI without sedation on Philips 1.5 Tesla Intera scanners (Netsch, 2001) at Texas Children's Hospital (Houston), the Rogers MRI Center, University of Texas Southwestern Medical Center (Dallas) or the Miami Children's Hospital (Miami) using comparable platforms and software. Regular quality assurance testing was performed on all three scanners including American College of Radiology phantom and Weisskoff testing for echo planar imaging (EPI) sequences, and all scanners were consistently noted to be within an acceptable range throughout the study.

DTI Acquisition

Transverse multislice spin echo, single-shot, EPI sequences (10,150.5 ms repetition time (TR), 90 ms echo time (TE), 2.7 mm thick slices with 0 mm gap) were applied. A 256 mm FOV (RFOV = 100%) was used with a measured voxel size of $2.69 \times 2.69 \times 2.7$ mm. Diffusivities will be evaluated along 15 directions (number of b-value = 2, low b-value = 0, and high-b value = 860 s/mm^2). Two acquisitions of high-b images were obtained and averaged to ensure better signal-to-noise ratio. A total number of 55 slices were acquired, and each acquisition took approximately 6 minutes.

Volumetric Acquisition

T1-weighted 3D sagittal acquisition series were used for volumetric analysis. Parameters included 15ms TR, 4.6 ms TE, 1.0 mm thick slices with 0 mm gap). A 256 mm FOV (RFOV = 100%) was used with a voxel size of $1.0 \times 1.0 \times 1.0$ mm.

DTI Analysis

Prior to computing FA maps with the Philips fiber tracking 4.1V3 Beta 2 software, shear and eddy current distortion and head motion artifact were corrected by using the Philips

PRIDE-registration tool (Netsch, 2001). ROIs of the CC were manually traced on the mid-sagittal plane following a previously published protocol (Wilde, et al., 2006) and included the genu/anterior, body/central and splenium/posterior sub-regions as well as the total CC. The automated Philips three-dimensional fiber tracking program was utilized to examine fiber tracks passing through the selected regions in the CC. The mean of FA and ADC, automatically calculated by the software, was used to quantitate DTI variables. The algorithm for fiber tracking is based upon the Fiber Assignment by Continuous Tracking (FACT) method (Mori, Crain, Chacko, & Vanzijl, 1999). If the FA in the voxels was less than 0.2 or if the angle between adjacent voxels was greater than 7 degrees, fiber tracking terminated.

Intra-rater and Inter-rater Reliability

DTI analysis was performed by two experienced raters following the specified protocol. To ensure intra-rater reliability, each ROI was independently analyzed by each rater twice. To examine inter-rater agreement, two trained raters performed analysis on each sub-region in a sample of six participants randomly selected (three TBI patients and three controls). Shrout-Fleiss intra-class correlation coefficients were performed and revealed satisfactory intra- (range: 0.937-1.000) and inter-rater reliability (range: 0.913-0.976)

Volumetric Analysis

Volumetric segmentation was performed with the FreeSurfer image analysis suite version 4.5.0 (Athinoula A. Martinos Center for Biomedical Imaging, 2005; <http://surfer.nmr.mgh.harvard.edu/>). In order to reduce bias with respect to a particular time point, the longitudinal processing scheme was initialized with a template based on the cross-sectionally processed scans at both three and 18 months. Details of the cross-sectional

(Fischl, et al., 2004) and longitudinal (Morey, et al., 2010) procedures have been described previously. Briefly, the cross-sectional processing involves intensity normalization (Sled, Zijdenbos, & Evans, 1998), automated Talairach transformation, the removal of non-brain tissue using a hybrid watershed/surface deformation procedure, and segmentation and labeling of the subcortical white matter and deep gray matter volumetric structures (Fischl, et al., 2002; Fischl, et al., 2004). Each scan was aligned to the unbiased template space, and the segmentation of the template was used as an initial approximation for the segmentation of each time point in the longitudinal processing. The use of the unbiased template for initializing the processing of cases in a longitudinal series is intended to reduce the random variation in the longitudinal procedure and improve the robustness and sensitivity of the overall longitudinal analysis, as stated by the Freesurfer developers. Results for each subject were visually inspected to ensure accuracy of registration, skull stripping, and segmentation. No editing was necessary in the automated segmentation of subcortical structures. The five standard subregions of the corpus callosum generated by FreeSurfer were used in analysis (anterior, mid-anterior, central, mid-posterior, and posterior) as well as a composite for the total corpus callosum, which was the sum of the volume of each of these sub-regions. The corpus callosum volumes derived in FreeSurfer are considered true volume estimates that compose the entire structure, with partial volume correction in order to account for the fraction of the structure in each border voxel. The anterior, central and posterior sub-regions used in volumetric analysis corresponded to genu/anterior, body/central and splenium/posterior sub-regions (respectively) used in DTI analysis.

Cognitive Measures

The baseline condition of the Flanker Arrow Test (Bunge, Dudukovic, Thomason,

Vaidya, & Gabrieli, 2002; Eriksen & Eriksen, 1974) was selected as a measure of information processing speed because we found that this measure of visual choice reaction time (without distraction) was related to corpus callosum integrity as measured by DTI variables (Levin, et al., 2008; Wilde, et al., 2006). One advantage of using this particular cognitive measure is that it is a language-free and multi-trial task with a high reliability (split-half $r = 0.96$) in the TBI population. Missing data were due to technical problems with this computerized task, the child's refusal to complete the task, or time constraints of the parent/guardian which precluded administration. There did not appear to be any source of systematic bias for the subjects with missing data such as greater injury severity (i.e., GCS) or cognitive impairment, and data was missing from all three sites. In the baseline condition of this task, a horizontal central arrow pointing to the left or to the right appeared on each trial. The child was asked to quickly press the button on the right or the left consistent with the direction that the arrow was pointing. There were 28 trials of the baseline task condition. Reaction time (RT) in each condition was the performance measure.

Data Analysis

Demographic statistics between groups were compared using t tests for continuous variables, namely, 1) age at injury, 2) Socioeconomic Composite Index (SCI) z -score, a measure of socioeconomic status (Yeates, et al., 1997), 3) maternal education, and 4) time post-injury for both the three and 18-month assessment time points. Categorical variables were analyzed using χ^2 (for gender) or Fisher's exact test (for handedness, race/ethnicity distribution, and mechanism of injury). We utilized t -tests to examine the group differences in FA and ADC of the CC sub-regions and total CC at both three and 18 months. Group differences in CC sub-region and total CC volumes at three and 18 months were also

analyzed with general linear models, including total intracranial volume (TICV) as a covariate to account for differences in head size. To examine the within-group changes over time in FA, ADC, and volumes of the CC sub-regions and total CC, paired *t*-tests were used for each group and each sub-region on the difference score, as calculated by three month minus 18 month values. A two-sample *t*-test was used to test the group difference on the change (two-way interaction of group by occasion). To examine the possibility that complicated-mild injury may differ in degree from more severe injuries on DTI, we repeated analyses excluding the participants with complicated-mild TBI and found that this did not change the results of the analyses. Within-group differences on the Flanker baseline reaction time (RT) between three and 18 months were tested using a paired *t*-test of the difference score between RT at three and 18 months. Pearson's partial correlation coefficients with age at injury and SCI controlled were used to examine the relation of DTI and volumetric variables to performance on Flanker baseline RT at both three and 18 months. The significance level was adjusted by using the family-wise Bonferroni method for the sub-regions (three sub-regions for DTI, $\alpha = 0.017$, and five sub-regions for volumetrics, $\alpha = 0.01$).

Results

Demographic and Injury Characteristics

The TBI group did not significantly differ from the OI group in age, gender, handedness, SCI, maternal education, or the duration of the post-injury interval at either the three- or 18-month assessment interval. As expected, groups differed significantly in the mechanism of injury, with more participants in the TBI group sustaining injury via motor vehicle and motorcycle crashes, and more participants in the OI group sustaining injury via

sports- and play-related injuries and falls. T-values (or χ^2 or Fisher exact test values) and *p*-values are presented in Table 1.

Group Differences at Three and 18 Months Post-Injury for DTI

At three months post-injury, the FA of the genu/anterior, body/central, splenium/posterior and total CC differed significantly between groups, with the TBI group demonstrating decreased FA. Similarly, ADC for the genu/anterior, splenium/posterior and total CC differed significantly between groups, with the TBI group demonstrating increased ADC. The ADC for the CC body/central sub-region exhibited a positive trend, but this was not considered significant after correction for multiple comparisons.

At the 18 month post-injury assessment, the FA for the genu/anterior and splenium/posterior sub-regions and the ADC for the genu/anterior and the body/central sub-regions and total CC differed significantly between groups, with lower FA and higher ADC in the TBI group. FA for the body/central sub-region and total CC as well as ADC for the splenium/posterior sub-region demonstrated trends after Bonferroni correction. Tables 2-3 detail means, standard deviations, t-values and *p*-values for all CC regions at both time points.

Table 1

Demographic and Injury Characteristics of TBI and OI Groups

Demographics	TBI Group (n=23), Mean ± SD	OI Group (n=25), Mean ± SD	t-value / χ^2 value	p-value
Age at Injury (years)	12.9 ± 3.2, range = 7.8 – 17.2	11.8 ± 2.7, range = 7.1 – 16.3	-1.20	0.235
Gender distribution	8 female, 15 male	7 female, 18 male	0.26*	0.613
Race/Ethnicity distribution	8 Caucasian, 1 AA, 1 American Indian, 13 Hispanic	10 Caucasian, 7 AA, 6 Hispanic, 1 Asian, 1 Biracial	Fisher's Exact	0.026
Maternal Education (yrs)	12.5 ± 3.4, range = 5.0 – 16.0	14.0 ± 2.7, range = 8.0 – 20.0	1.71	0.094
Handedness	22 right, 1 left	21 right, 4 left	Fisher's Exact	0.350
Mechanism of Injury (accident type)	12 MVC, 4 Motorcycle, 2 RV, 1 Bicycle, 2 Fall, 2 Hit by motor vehicle	1 Motorcycle, 1 RV, 7 Fall, 1 Hit by objects, 14 Sports, 1 Other	Fisher's Exact	0.0001
Glasgow Coma Score	7.5 ± 4.1; range = 3.0 – 15.0	N/A	N/A	N/A
Time post-injury: 3M (months)	4.0 ± 0.9, range = 2.5 – 5.3	4.2 ± 1.0, range = 2.7 – 7.1	0.49	0.629
Time post-injury: 18M (months)	18.9 ± 1.5, range = 16.7 – 22.6	18.8 ± 1.3, range = 16.6 – 20.9	-0.26	0.795

Note. TBI = traumatic brain injury; OI = orthopedically injured; MVC = Motor vehicle crash, †RV = Recreation vehicle crash. M=mean. SD=Standard Deviation. AA = African American, *=performed with Chi-square test.

Table 2

Group Difference of the CC for FA at three and 18 months

Regions	Interval	TBI (Mean \pm SD)	OI (Mean \pm SD)	F value	p value
Total CC	3M	0.42 \pm 0.03	0.47 \pm 0.02	5.03	0.0001
	18M	0.43 \pm 0.03	0.47 \pm 0.02	2.36	0.043
Genu	3M	0.42 \pm 0.03	0.47 \pm 0.03	2.37	0.0001
	18M	0.43 \pm 0.03	0.48 \pm 0.02	6.97	0.0001
Body	3M	0.41 \pm 0.04	0.45 \pm 0.03	4.16	0.0001
	18M	0.42 \pm 0.03	0.46 \pm 0.02	2.36	0.043
Splenum	3M	0.46 \pm 0.04	0.49 \pm 0.02	4.70	0.0004
	18M	0.47 \pm 0.04	0.51 \pm 0.02	3.64	0.003

Note. CC = corpus callosum. SD = standard deviation. FA = fractional anisotropy. Bold typeface indicates significance after Bonferroni correction for multiple comparisons.

Table 3

Group Difference of the CC for ADC at three and 18 months

Regions	Interval	TBI (Mean \pm SD)	OI (Mean \pm SD)	F value	p value
Total CC	3M	0.98 \pm 0.07	0.93 \pm 0.05	-3.03	0.04
	18M	0.99 \pm 0.07	0.91 \pm 0.06	-4.30	0.0001
Genu	3M	0.91 \pm 0.03	0.86 \pm 0.04	-3.80	0.004
	18M	0.93 \pm 0.07	0.85 \pm 0.05	-4.58	0.0001
Body	3M	0.97 \pm 0.10	0.92 \pm 0.07	-2.06	0.046
	18M	0.97 \pm 0.08	0.90 \pm 0.06	-3.43	0.001
Splenum	3M	1.02 \pm 0.09	0.95 \pm 0.06	-3.18	0.003
	18M	1.04 \pm 0.10	0.95 \pm 0.07	32.30	0.049

Note. CC = corpus callosum. SD = standard deviation, ADC = apparent diffusion coefficient. ADC values are represented in 10^{-3} mm²/sec. Bold typeface indicates significance after Bonferroni correction for multiple comparisons.

Longitudinal DTI Analyses

Both groups demonstrated increased FA in total CC and all CC sub-regions at 18 months as compared to three months post-injury. However, only the increase of FA in the splenium/posterior sub-region in both the TBI ($t(22) = -3.36, p = 0.003$) and OI ($t(24) = -2.76, p = 0.011$) groups reached significance after correction for multiple comparisons. The TBI group showed a marginally significant increase in the FA for the total CC ($t(22) = -2.21, p = 0.038$) over time. The OI group showed a marginally significant increase of FA in the total CC ($t(24) = -2.04, p = 0.053$) and marginally significant decreases in ADC for the body/central subregion ($t(24) = 2.10, p = 0.047$) and total CC ($t(24) = 1.76, p = 0.092$). No significant between-group differences for longitudinal changes were noted in any region. Figure 1 illustrates the change between three and 18 months for FA and ADC of both the splenium/posterior sub-region of the CC and the total CC in both groups.

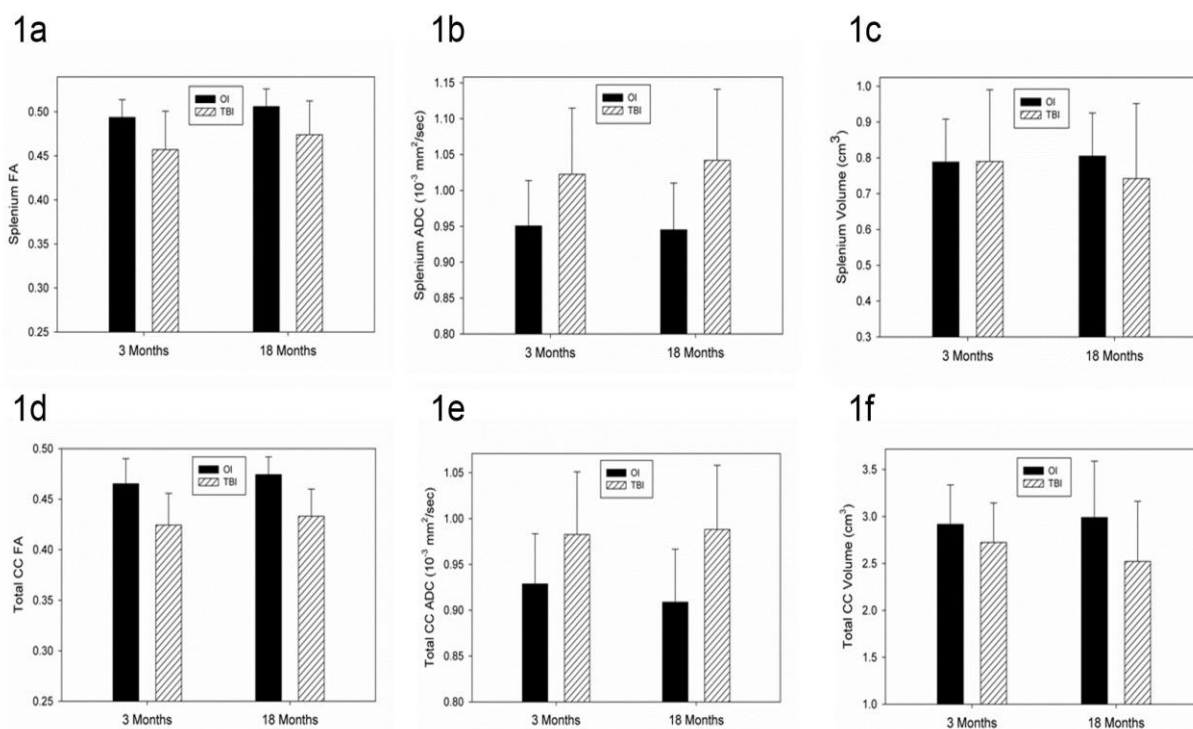


Figure 1. Bar graphs with error bars illustrating the longitudinal change between three and 18 months post-injury in FA (a) and ADC (b) as measured by quantitative DTI tractography, and volume (c) as measured by volumetric analysis in the splenium/posterior sub-region of the CC in both the TBI and OI groups. Note that the FA remains significantly lower in the TBI group as compared to the OI group, but increases comparably to the OI group. The ADC decreases over time in the OI group, as would be expected given normal developmental change, but ADC in the TBI group continues to increase at a modest rate, which is unexpected given the typical relation between FA and ADC. The volume of the splenium increases in the OI group, as expected given normal developmental change that is occurring in this age range, but evidences continued degenerative change in the TBI group over time. Changes in the total CC are reflected in FA (d), ADC (e) as measured by quantitative DTI tractography, and volume (f) as measured by volumetric analysis.

Relation of DTI to Cognitive Functioning

Cognitively, the OI group demonstrated a significant improvement in speed of information processing over time ($t(18) = 2.55, p = 0.02$). The speed of information processing did not differentiate the TBI and OI groups at either three or 18 month occasions when all participants were included. However, when the participants with complicated-mild injuries were excluded, results were unchanged at three months, but there was a trend for group difference at 18 months ($t(28) = -1.90, p = .086, d = 1.25$) such that the participants with TBI had slower RTs.

At three months post-injury in the TBI group, FA in the splenium ($\rho = -0.58, p = 0.008$) and total CC ($\rho = -0.55, p = 0.012$) were significantly correlated with baseline

condition processing speed. Higher FA was related to faster reaction time. These correlations became stronger at the 18 month post-injury occasion (for the splenium/posterior sub-region: $\rho = -0.84$, $p = 0.001$; for total CC: $\rho = -0.71$, $p = 0.014$). Figure 2 reflects the relation between FA in the splenium/posterior sub-region of the CC and reaction time on the Flanker task in each group.

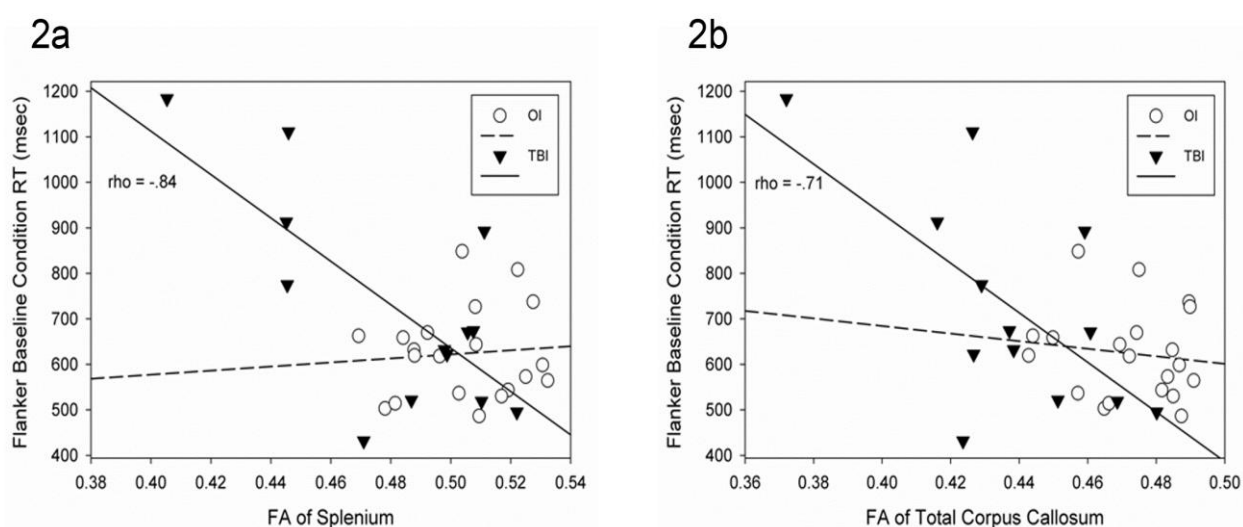


Figure 2. Scatterplots with regression lines demonstrating the relation between Flanker baseline condition RT and FA of the splenium/posterior sub-region (a) and the total CC (b) at 18 months post-injury in the TBI and OI groups. Note the significant correlation for the TBI group.

Group Differences at Three and 18 Months Post-Injury for Volumetrics

At three months post-injury, the mid-anterior ($F(1,37) = 6.25$, $p = 0.017$) and body/central ($F(1,37) = 5.36$, $p = 0.026$) sub-regions and total CC ($F(1,37) = 4.27$, $p = 0.046$) marginally differed between the groups, though the genu/anterior and

splenium/posterior regions did not significantly differ (see Table 4). In each case, the TBI group exhibited decreased volume in the sub-region relative to the OI comparison group.

At 18 months post-injury, the genu/anterior ($F(1,37) = 7.76, p = 0.008$), mid-anterior ($F(1,37) = 15.13, p = 0.0004$), body/central ($F(1,37) = 10.20, p = 0.003$), and mid-posterior ($F(1,37) = 8.96, p = 0.005$) sub-regions of the CC as well as the total CC ($F(1,37) = 11.83, p = 0.002$) significantly differed between groups (see Table 4 for least squares means), again with the TBI group demonstrating significantly decreased volume relative to the OI group.

Longitudinal Volumetric Analyses

In terms of within group differences, in the OI group, the genu/anterior ($p = 0.010$), mid-posterior ($p = 0.002$), and splenium/posterior ($p = 0.0008$) sub-regions of the CC as well as the total CC ($p = 0.001$) demonstrated significant volume increase between three and 18 months post-injury. Mid-anterior and body/central sub-regions marginally differed, again demonstrating an increase in volume over time, but this change was not significant. In contrast, the TBI group demonstrated decreases in volume between three and 18 months post-injury in the genu/anterior ($p = 0.009$) and mid-posterior ($p = 0.007$) sub-regions and total CC ($p = 0.012$). Change in CC volume between three and 18 months revealed significant between-group differences in the genu/anterior (Satterthwaite $t(17.8) = -3.70, p = .002$), mid-anterior (Satterthwaite $t(20) = -2.95, p = 0.008$), mid-posterior (Satterthwaite $t(20) = -4.19, p = 0.0004$) and splenium/posterior (Satterthwaite $t(16.5) = -3.20, p = 0.005$) regions and the total CC (Satterthwaite $t(17.2) = -3.73, p = 0.002$). A marginally significant difference was noted for the body/central sub-region ($t(38) = -1.82, p = 0.077$). Figures 1c and 2c illustrate the pattern of change between three and 18 months in the TBI and OI groups for the splenium/posterior sub-region and the total CC, respectively.

Table 4

Volumetric Differences in Corpus Callosum Sub-regions at three and 18 months

Regions	Interval	TBI (LSM)	OI (LSM)	F value	p value
Total CC	3M	2.72	2.92	4.27	0.46
	18M	2.52	2.99	11.83	0.002
Anterior	3M	0.72	0.79	3.19	0.082
	18M	0.67	0.80	7.76	0.008
Mid-anterior	3M	0.41	0.46	6.25	0.017
	18M	0.37	0.47	15.13	0.0004
Central	3M	0.40	0.47	5.36	0.026
	18M	0.38	0.48	10.20	0.003
Mid-posterior	3M	0.40	0.42	1.57	0.218
	18M	0.36	0.44	8.96	0.005
Posterior	3M	0.79	0.79	0.11	0.74
	18M	0.74	0.81	2.14	0.152

Note. LSM = least squares means. Volumetric measures are represented in cubic centimeters. Bold typeface indicates significance after Bonferroni correction for multiple comparisons.

Relation of Volume to Cognitive Function

There were no significant correlations between processing speed and volumes of the sub-regions of the corpus callosum in either group at three and 18 month post-injury interval assessments. Total corpus callosum volume was marginally related to processing speed at 18 months in the OI group only ($\rho = -0.433$, $p = 0.06$), with greater volume associated with faster processing speed.

Discussion

This study demonstrated continued late degenerative change as reflected in the gross morphometry of nearly all regions of the corpus callosum as measured by volumetric analysis between three and 18 months post-injury in the TBI group. These degenerative changes were most prominent in the genu/anterior, mid-posterior and splenium/posterior sub-regions of the corpus callosum. In contrast, the genu/anterior, mid-posterior, and splenium/posterior sub-regions of the corpus callosum demonstrated significant volume increases in the comparison group of children with orthopedic injury, consistent with known developmental changes in this age range (Lobel, et al., 2009; Zhang, et al., 2005). Previous developmental studies have demonstrated that the thinly myelinated and densely packed fibers more characteristic of the genu mature later than those with thicker myelination (Kochunov, et al., 2010), and hence the developmental changes may be greater in these regions during the age range of the children whom we studied. It is also possible that these fibers that may sustain a differential vulnerability to aging (Kochunov, et al., 2010) or insult, including TBI-induced axonal injury in particular (Reeves, Phillips, & Povlishock, 2005). Traumatic-induced atrophy of the corpus callosum likely occurs as a consequence of complex neuropathological features that involve both direct trauma to the CC (Mac Donald,

Dikranian, Song, et al., 2007; Parizel, et al., 1998) as well as secondary degeneration of a Wallerian type occurring because of diffuse damage elsewhere in the brain disrupts the integrity of white matter tracts (Di Paola, et al., 2010).

Typical CC development in childhood follows a predictable course of myelination, which at least in animal models also relates to environmental complexity (Markham, Herting, Luszbek, Juraska, & Greenough, 2009). In the typically-developing brain, this likely also leads to complex brain-environment-developmental interactions resulting in increased CC volume during the age ranges of the children in this study and as confirmed in the results of the OI participants. However, brain injury may induce deficits in cognitive processing which likely diminish the child's ability to process complex material (Taylor, 2004). Hampered by slowed processing speed and diminished integration of inter-hemispheric information due to the CC damage, theoretically this could interact negatively with development and minimize CC growth trajectories. As reflected in further reduced volume over time, the TBI children did not exhibit maturation-related volume increases in the CC. Likewise, it is not unexpected that processing speed would improve in typically-developing children, as was observed in the children with OI, but not TBI participants. These findings support the notion that brain injury disrupts normal white matter maturation and development, disconnecting the typical link with maturational changes that improve processing speed.

However, the current study shows a most interesting apparent adaption in CC functioning in that children with TBI could adequately perform the Flanker Task and at a level that did not differ from OI controls at the three month baseline or 18 month follow-up. This suggests that within the initial three month post-injury time frame, adaptations in CC functioning were sufficient for these patients to adequately perform the task despite the

volume and DTI changes that had already occurred at that stage. In case of surgical treatment of the CC, typically performed as a procedure to treat chronic epilepsy, adaptive rerouting of CC pathways has long been documented (Bloom & Hynd, 2005; Tanriverdi, Olivier, Poulin, Andermann, & Dubeau, 2009). This is likely part of the explanation within the TBI group that part of the recovery from TBI is some form of programmed adaptive mechanisms that engage intact tracts to adapt. It is also possible that new inter- and intra-hemispheric communications could potentially be formulated via alternative routes, such as the anterior commissure (Patel, Toussaint, Charles-Edwards, Lin, & Batchelor, 2010). Even though the TBI group was not significantly slower than the OI group on the Flanker task, DTI findings did relate to processing speed in the TBI group in the splenium/posterior sub-region, which became stronger in this group over time.

The continued degenerative changes over this time interval on volumetrics in the TBI group were not reflected in longitudinal changes in DTI metrics such as FA. Despite loss of volume in the TBI group in some sub-regions, likely reflective of some degree of neuronal death and axonal degeneration, the FA generally increased in both the TBI and the OI groups in all regions. In animal studies, histological findings have related tissue volume loss to cellular loss (Grady, Charleston, Maris, Witgen, & Lifshitz, 2003) and specifically, CC volume loss to neuronal loss (Bramlett & Dietrich, 2002). On the other hand, DTI is likely showing how injured neurons, while damaged, recover over time (Kumar, et al., 2010), at least to some degree. In the current study, these two methods likely reflect quite different neuropathological end-points over time where reduced volume reflects overall neuronal loss whereas DTI findings more specifically reflect axonal integrity, restorative and adaptive processes that develop over time after injury. Figure 3 illustrates the qualitative differences

in DTI tractography over time that compliment the quantitative findings we describe in this study in one participant. However, it should be noted that although FA in the TBI group did increase, ADC in the TBI group did not decrease as would have been anticipated given the traditional inverse relation between FA and ADC, and in fact, ADC also increased over time. This suggests that the expected developmental trajectory reflected in FA increase and ADC increase observed in the comparison group may, in fact, be altered somewhat by TBI despite the apparent increase in FA. As both FA and ADC may be impacted by multiple factors related to the microstructural characteristics of the tissue, including fiber density, axonal diameter and the ratio of intracellular/extracellular space, further investigation into the more specific nature of these changes is warranted.

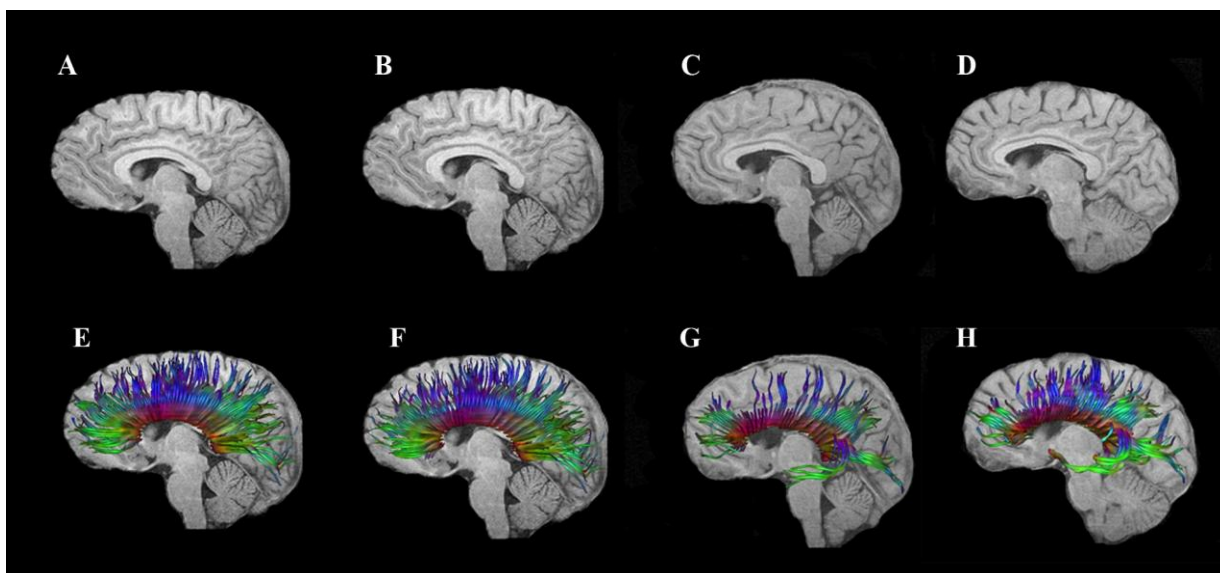


Figure 3. T1-weighted sagittal images of a 16 year old male adolescent with orthopedic injury at three months (a) and 18 months (b) post-injury. T1-weighted images of a 15-year old male adolescent with moderate TBI (Glasgow Coma Scale score of 9) at three months (c)

and 18 months (d) post injury is also presented. Note the subtle atrophy of the CC in the TBI child. DTI tractography of the CC is overlaid on the T1-weighted image for the adolescent with OI at three months (e) and 18 months (f) post-injury, which reflects subtle qualitative increase in the fiber density. Similarly, the DTI tractography of the CC overlaid on the T1-weighted imaging from the adolescent with TBI at three months (g) and 18 months (h) post-injury reveals qualitative increase in both the fiber density and intensity of the CC over time, though the density of fibers is still significantly less than that of the comparison OI participant

Although the trajectory of change in FA for both groups followed a similar slope post-injury, the difference between the TBI and OI groups remained significant, with the TBI group exhibiting a significantly lower mean FA at both time points in several regions. This also reflects that DTI changes such as FA may be more specific to adaptive mechanism of recovery than are traditional volumetric measures (van der Zijden, van der Toorn, van der Marel, & Dijkhuizen, 2008). This difference further indicates that neuropathologically DTI is assessing something quite different than just neuronal loss or axonal degradation. Because DTI did relate to processing speed, it may be the more sensitive biomarker of actual CC integrity than measuring atrophic changes through volume loss. Because DTI is such a new technology, studies are just now being done to ascertain whether microstructural changes as found with DTI may occur independently of volumetric parenchymal changes (Canu, et al., 2010). Clearly, multimodality imaging studies may be useful in further examination of TBI-related consequences to brain parenchyma.

Strengths, Limitations and Future Directions

Few studies have specifically examined longitudinal changes following TBI using advanced imaging modalities such as volumetric analysis and DTI (Bendlin, et al., 2008; Kumar, et al., 2009; Kumar, et al., 2010; Sidaros, et al., 2008; Sidaros, et al., 2009), and to our knowledge, no study has examined these changes on DTI in a pediatric TBI population (Levin, et al., 2000). Strengths of this study include its prospective, longitudinal design and its use of an orthopedically-injured comparison group.

We limited this investigation to changes in the corpus callosum, but additional brain regions should be examined in future studies. As we have shown elsewhere, diffuse changes in the brain result from moderate to severe TBI (Bigler, et al., 2010) including thinning of the cerebral cortex (Merkley, et al., 2008) but how these diffuse changes relate specifically to the atrophic changes of the CC and cognitive outcome is not known at this time. Additionally, other methods of DTI analysis such as voxel based analysis and region of interest analysis will be applied in future studies to examine these differences.

We emphasize that these analyses represent group trends, and we acknowledge the possibility that different patterns of change over time may emerge in some individuals with TBI based upon factors related to the heterogeneity of injury type and location, age at injury, mechanism of injury, and pre- and post-injury characteristics that may render some individuals more resilient to the effects of injury than others. Future studies may examine some of these factors.

Finally, missing data may have limited the power to detect differences in the behavioral and cognitive measures. For instance, the effect size for group differences on the Flanker task RT at three months was 0.37, which is small to moderate, but the power to

detect a significant difference was only of 33.7%. Similarly at 18 months, the effect size was 0.62, which is moderate to large, but the power to detect a significant difference was only 43.4%.

Conclusions

The current findings indicate that at the macro- and micro-structural level, two seemingly opposite trajectories were noted following moderate to severe TBI in children and adolescents. Volumetric analyses demonstrated degeneration in the CC over time, whereas DTI findings showed some degree of increase in the FA over time, indicative of maturation or recovery. FA was also related to speed of information processing at both time points, though even more strongly at the 18 month post-injury interval. White matter changes as measured by multimodality imaging studies may be useful in better understanding changes indicative of both degeneration and residual loss of tissue and cognitive difficulty as well as plasticity and recovery, particularly in an age range that is also undergoing dynamic developmental change.

References

- Alexander, A. L., Lee, J., E., Lazar, M., & Field, A. S. (2007). Diffusion tensor imaging of the brain. *The Journal of the American Society for Experimental NeuroTherapeutics*, 4, 316-329.
- Anderson, C. V., & Bigler, E. D. (1994). The role of caudate nucleus and corpus callosum atrophy in trauma-induced anterior horn dilation. *Brain Injury*, 8(6), 565-569.
- Arfanakis, K., Haughton, V. M., Carew, J. D., Rogers, B. P., Dempsey, R. J., & Meyerand, M. E. (2002). Diffusion tensor MR imaging in diffuse axonal injury. *American Journal of Neuroradiology*, 23, 794-802.
- Ashwal, S., Holshouser, B. A., & Tong, K. A. (2006). Use of advanced neuroimaging techniques in the evaluation of pediatric traumatic brain injury. *Developmental Neuroscience*, 28, 309-326.
- Assaf, Y., Beit-Yannai, E., Shohami, E., Berman, E., & Chohen, Y. (1997). Diffusion- and T2-weighted MRI of closed-head injury in rats: a time course study and correlation with histology. *Magnetic Resonance Imaging*, 15(1), 77-85.
- Aukema, E. J., Caan, M. W. A., Oudhuis, N., Majoie, C. B. L. M., Vos, F. M., Reneman, L., et al. (2009). White matter fractional anisotropy correlates with speed of processing and motor speed in young childhood cancer survivors. *International Journal of Radiation Oncology Biology Physics*, 74, 837-843.
- Babikian, T., Marion, S. D., Copeland, S., Alger, J. R., O'Neill, J., Cazalis, F., et al. (in press). Metabolic levels in the corpus callosum and their structural and behavioral correlates after moderate to severe pediatric TBI. *Journal of Neurotrauma*.

- Battistone, M., Woltz, D., & Clark, E. (2008). Processing speed deficits associated with traumatic brain injury: processing inefficiency of cautiousness? *Applied Neuropsychology, 15*, 69-78.
- Bazarian, J. J., Zhong, J., Blyth, B., Zhu, T., Kavcic, V., & Peterson, D. (2007). Diffusion tensor imaging detects clinically important axonal damage after mild traumatic brain injury: a pilot study. *Journal of Neurotrauma, 24*, 1447-1459.
- Beauchamp, M. H., Anderson, V. A., Catroppa, C., Maller, J. J., Godfrey, C., Rosenfeld, J. V., et al. (2009). Implications of reduced callosal area for social skills after severe traumatic brain injury in children. *Journal of Neurotrauma, 26*(10), 1645-1654.
- Belanger, H. G., Vanderploeg, R. D., Curtiss, G., & Warden, D. L. (2007). Recent neuroimaging techniques in mild traumatic brain injury. *Journal of Neuropsychiatry and Clinical Neuroscience, 19*, 5-20.
- Benavidez, D. A., Fletcher, J. M., Hannay, H. J., Bland, S. T., Caudle, S. E., Mendelsohn, D. B., et al. (1999). Corpus callosum damage and interhemispheric transfer of information following closed head injury in children. *Cortex, 35*, 315-336.
- Bendlin, B. B., Ries, M. L., Lazar, M., Alexander, A. L., Dempsey, R. J., Rowley, H. A., et al. (2008). Longitudinal changes in patients with traumatic brain injury assessed with diffusion-tensor and volumetric imaging. *NeuroImage, 42*: 503-514
- Benson, R. R., Meda, S. A., Vasudevan, S., Kou, Z., Govindarajan, K. A., Hanks, R. A., et al. (2007). Global white matter analysis of diffusion tensor images is predictive of injury severity in traumatic brain injury. *Journal of Neurotrauma, 24*(3), 446-459.
- Biegon, A., Eberling, J. L., & Richardson, B. C. (1994). Human corpus callosum in aging and Alzheimer's disease: a magnetic resonance imaging study. *Neurobiology of*

- Aging*, 15(4), 393-397.
- Bigler, E. D., Abildskov, T., Wilde, E. A., McCauley, S. R., Li, X., Merkley, T. L., et al. (2010). Diffuse damage in pediatric traumatic brain injury: a comparison of automated versus operator-controlled quantification methods. *NeuroImage*, 50(3), 1017-1026.
- Bloom, J. S., & Hynd, G. W. (2005). The role of the corpus callosum in interhemispheric transfer of information: excitation or inhibition? *Neuropsychology Review*, 15(2), 59-71.
- Bramlett, H. M., & Dietrich, W. D. (2002). Quantitative structural changes in white and gray matter 1 year following traumatic brain injury in rats. *Acta Neuropathologica*, 103(6), 607-614.
- Bunge, S. A., Dudukovic, N. M., Thomason, M. E., Vaidya, C. J., & Gabrieli, J. D. (2002). Immature frontal lobe contributions to cognitive control in children: evidence from fMRI. *Neuron*, 33(2), 301-311.
- Canu, E., McLaren, D. G., Fitzgerald, M. E., Bendlin, B. B., Zoccatelli, G., Alessandrini, F., et al. (2010). Microstructural diffusion changes are independent of macrostructural volume loss in moderate to severe Alzheimer's disease. *Journal of Alzheimer's disease*, 19(3).
- Chepuri, N. B., Yen, Y- F., Burdette, J. H., Li, H., Moody, D. M., & Maldjian, J. A. (2002). Diffusion anisotropy in the corpus callosum. *American Journal of Neuroradiology*, 23, 803-808.
- Chu, Z., Wilde, E. A., Hunter, J. V., McCauley, S. R., Bigler, E. D., Troyanskaya, M., et al. (2010). Voxel-based analysis of diffusion tensor imaging in mild traumatic brain

- injury in adolescents. *American Journal of Neuroradiology*, 31(2), 340-346.
- Di Paola, M., Luders, E., Di Iulio, F., Cherubini, A., Passafiume, D., Thompson, P. M., et al. (2010). Callosal atrophy in mild cognitive impairment and Alzheimer's disease: different effects in different stages. *NeuroImage*, 49(1), 141-149.
- Ducreux, D., Huynh, I., Fillard, P., Renoux, J., Petit-Lacour, M. C., Marsot-Dupuch, K., et al. (2005). Brain MR diffusion tensor imaging and fibre tracking to differentiate between two diffuse axonal injuries. *Neuroradiology*, 47, 604-608.
- Eriksen, B. A., & Eriksen, C. W. (1974). Effects of noise letters upon the identification of a target letter in a nonsearch task. *Perception & Psychophysics*, 16(1), 143-149.
- Ewing-Cobbs, L., Hasan, K. M., Prasad, M. R., Kramer, L., & Bachevalier, J. (2006). Corpus callosum diffusion anisotropy correlates with neuropsychological outcomes in twins discordant for traumatic brain injury. *American Journal of Neuroradiology*, 27, 879-881.
- Ewing-Cobbs, L., Prasad, M. R., Swank, P., Kramer, L. S., Cox, J. C. Jr., Fletcher, J. M., et al. (2008). Arrested development and disrupted callosal microstructure following pediatric traumatic brain injury: relation to neurobehavioral outcomes. *NeuroImage*, 42, 1305-1315.
- Fischl, B., Salat, D. H., Busa, E., Albert, M., Dieterich, M., Haselgrove, J. C., et al. (2002). Whole brain segmentation: Automated labeling of neuroanatomical structures in the human brain. *Neuron*, 33, 341-355.
- Fischl, B., Salat, D. H., van der Kouwe, A. J., Makris, N., Segonne, F., Quinn, B. T., et al. (2004). Sequence-independent segmentation of magnetic resonance images. *NeuroImage*, 23, S69-S84.

- Gorrie, C., Duflou, J., Brown, J., Gibson, T., & Waite, P. M. (2001). Extent and distribution of vascular brain injury in pediatric road fatalities. *Journal of Neurotrauma*, *18*, 849-860.
- Grady, M. S., Charleston, J. S., Maris, D., Witgen, B. M., & Lifshitz, J. (2003). Neuronal and glial cell number in the hippocampus after experimental traumatic brain injury: analysis by stereological estimation. *Journal of Neurotrauma*, *20*(10), 929-941.
- Huisman, T. A. G. M., Schwamm, L. H., Schaefer, P. W., Koroshetz, W. J., Shetty-Alva, N., Ozsunar, Y., et al. (2004). Diffusion tensor imaging as potential biomarker of white matter injury in diffuse axonal injury. *American Journal of Neuroradiology*, *25*, 370-376.
- Inglese, M., Makani, S., Johnson, G., Cohen, B., Silver, J., Gonen, O., et al. (2005). Diffuse axonal injury in mild traumatic brain injury: a diffusion tensor imaging study. *Journal of Neurosurgery*, *103*, 298-303.
- Johansson, B., Berglund, P., & Ronnback, L. (2009). Mental fatigue and impaired information processing after mild and moderate traumatic brain injury. *Brain Injury*, *23*, 1027-1040.
- Jokinen, H., Ryberg, C., & Halska, H. (2007). Corpus callosum atrophy is associated with mental slowing and executive deficits in subjects with age-related white matter hyperintensities: the LADIS study. *Journal of Neurology, Neurosurgery, Psychiatry*, *78*, 491-496.
- Kim, J., Avants, B., Patel, S., Whyte, J., Coslett, B. H., Pluta, J., et al. (2008). Structural consequences of diffuse traumatic brain injury: a large deformation tensor-based morphometry study. *NeuroImage*, *2008*(39), 1014-1026.

- Kochunov, P., Williamson, D. E., Lancaster, J., Fox, P., Cornell, J., Blangero, J., et al. (in press). Fractional anisotropy of water diffusion in cerebral white matter across the lifespan. *Neurobiology of Aging*.
- Kraus, M. F., Susmaras, T., Caughlin, B. P., Walker, C. J., Sweeney, J. A., & Little, D. M. (2007). White matter integrity and cognition in chronic traumatic brain injury: a diffusion tensor imaging study. *Brain*, *130*, 2608-2519.
- Kumar, R., Husain, M., Gupta, R. K., Hasan, K. M., Haris, M., Agarwal, A. K., et al. (2009). Serial changes in the white matter diffusion tensor imaging metrics in moderate traumatic brain injury and correlation with neuro-cognitive function. *Journal of Neurotrauma*, *26*(4), 481-495.
- Kumar, R., Saksena, S., Husain, M., Srivastava, A., Rathore, R. K., Agarwal, S., et al. (2010). Serial changes in diffusion tensor imaging metrics of corpus callosum in moderate traumatic brain injury patients and their correlation with neuropsychometric tests: a 2-year follow-up study. *The Journal of Head Trauma Rehabilitation*, *25*(1), 31-42.
- Langlois, J. A., Rutland-Brown, W., & Thomas, K. E. (2005). The incidence of traumatic brain injury among children in the United States: differences by race. *The Journal of Head Trauma Rehabilitation*, *20*(3), 229-238.
- Levin, H. S., Benavidez, D., Verger-Maestre, K., Perachio, N., Song, J., Mendelsohn, D., et al. (2000). Reduction of corpus callosum growth after severe traumatic brain injury in children. *Neurology*, *54*, 647-653.
- Levin, H. S., Wilde, E. A., Chu, Z., Yallampalli, R., Hanten, G., Li, X., et al. (2008). Diffusion tensor imaging in relation to cognitive and function outcome of traumatic

- brain injury in children *Journal of Head Trauma Rehabilitation*, 23(4), 197-208.
- Levin, H. S., Williams, D. H., Valastro, M., Eisenberg, H. M., Crofford, M. J., & Handei, S. F. (1990). Corpus callosal atrophy following closed head injury: detection with magnetic resonance imaging. *Journal of Neurosurgery* 73, 77-81.
- Little, D. M., Kraus, M. F., Joseph, J., Geary, E. K., Susmaras, T., Zhou, X. J., et al. (2010). Thalamic integrity underlies executive dysfunction in traumatic brain injury. *Neurology*, 74(7), 558-564.
- Lobel, U., J., S., Gullmar, D., Kaiser, W. A., Reichenbach, J. R., & Mentzel, H. J. (2009). Diffusion tensor imaging: the normal evolution of ADC, RA, FA, and eigenvalues studied in multiple anatomical regions of the brain. *Neuroradiology*, 51(4), 253-263.
- Mac Donald, C. L., Dikranian, K., Bayly, P., Holtzman, D., & Brody, D. (2007). Diffusion tensor imaging reliably detects experimental traumatic axonal injury and indicates approximate of injury. *The Journal of Neuroscience*, 27(44), 11869-11876.
- Mac Donald, C. L., Dikranian, K., Song, S. K., Bayly, P., Holtzman, D. M., & Brody, D. L. (2007). Detection of traumatic axonal injury with diffusion tensor imaging in a mouse model of traumatic brain injury. *Experimental Neurology*, 205(1), 116-131.
- Madigan, N. K., DeLuca, J., Diamond, B. J., Tramontano, G., & Averiall, A. (2000). Speed of information processing in traumatic brain injury: modality-specific factors. *Journal of Head Trauma Rehabilitation*, 15(3), 943-956.
- Markham, J. A., Herting, M. M., Luszpak, A. E., Juraska, J. M., & Greenough, W. T. (2009). Myelination of the corpus callosum in male and female rats following complex environment housing during adulthood. *Brain Research*, 1288, 9-17.
- Mayer, A. R., Ling, J., Mannell, M. V., Gasparovic, C., Phillips, J. P., Doezema, D., et al.

- (2010). A prospective diffusion tensor imaging study in mild traumatic brain injury. *Neurology*, 74(8), 643-650.
- Merkley, T. L., Bigler, E. D., Wilde, E. A., McCauley, S. R., Hunter, J. V., & Levin, H. S. (2008). Diffuse changes in cortical thickness in pediatric moderate-to-severe traumatic brain injury. *Journal of Neurotrauma*, 25(11), 1343-1345.
- Morey, R. A., Selgrade, E. S., Wagner, H. R., 2nd, Huettel, S. A., Wang, L., & McCarthy, G. (2010). Scan-rescan reliability of subcortical brain volumes derived from automated segmentation. *Hum Brain Mapp*, 31(11), 1751-1762
- Mori, S., Crain, B. J., Chacko, V. P., & Vanzijl, P. C. (1999). Three-dimensional tracking of axonal projections in the brain by magnetic resonance imaging. *Annls of Neurology*, 45(2), 265-269.
- Mori, S., & Zhang, J. (2006). Principles of diffusion tensor imaging and its applicaitons to basic neuroscience research. *Neuron*, 51, 527-539.
- Mukherjee, P., Berman, J. I., Chung, S. W., Hess, C. P., & Henry, R. G. (2008). Diffusion tensor MR imaging and fiber tractography: theoretic underpinnings. *American Journal of Neuroradiology*, 29, 632-641.
- Nakayama, N., Okumura, A., Shinoda, J., Yasokawa, Y. T., Yoshimura, S. I., & Iwama, T. (2006). Evidence for white matter disruption in traumatic brain injury without macroscopic lesions. *J Neurol Neurosurg Psychiatry*, 77, 850-855.
- Netsch, T. (2001). *Towards real-time multi-modality 3-D medical image registration*. ICCV, Vancouver, vol, pp 718-725.
- Newcombe, V. F. J., Williams, G. B., Nortje, J., Bradley, P. G., Harding, S. G., Smielewski, P., et al. (2007). Analysis of acute traumatic axonal injury using diffusion tensor

- imaging. *British Journal of Neurosurgery*, 21(4), 340-348.
- Niogi, S. N., Mukherjee, P., Ghajar, J., Johnson, C., Koslter, R. A., Sarkar, R., et al. (2008). Extent of microstructural white matter injury in postconcussive syndrome correlates with impaired cognitive reaction time: a 3T diffusion tensor imaging study of mild traumatic brain injury. *American Journal of Neuroradiology*, 29, 967-973.
- Pannek, K., Mathias, J. L., Bigler, E. D., Brown, G., Taylor, J. D., & Rose, S. (2010). An automated strategy for the delineation and parcellation of commissural pathways suitable for clinical populations utilising high angular resolution diffusion imaging tractography. *NeuroImage*, 50(3), 1044-1053.
- Parizel, P. M., Ozsarlak., Van Goethem, J. W., van den Hauwe, L., Dillen, C., Verlooy, J., et al. (1998). Imaging findings in diffuse axonal injury after closed head trauma. . *European Radiology*, 8(6), 960-965.
- Patel, M. D., Toussaint, N., Charles-Edwards, G. D., Lin, J. P., & Batchelor, P. G. (in press). Distribution and fibre field similarity mapping of the human anterior commissure fibres by diffusion tensor imaging. *Magnetic Resonance Materials in Physics, Biology and Medicine*.
- Povlishock, J. T., & Katz, D. I. (2005). Update of neuropathology and neurological recovery after traumatic brain injury. *Journal of Head Trauma Rehabilitation*, 20(1), 76-94.
- Ptak, T., Sheridan, R. L., Rhea, J. T., Gervasini, A. A., Yun, J. H., Curran, M. A., et al. (2003). Cerebral fractional anisotropy score in trauma patients: A new indicator of white matter injury after trauma. *American Journal of Radiology*, 181, 1401-1407.
- Reeves, T. M., Phillips, L. L., & Povlishock, J. T. (2005). Myelinated and unmyelinated axons of the corpus callosum differ in vulnerability and functional recovery following

- traumatic brain injury. *Experimental Neurology*, 196(1), 126-137.
- Rugg-Gunn, F. J., Symms, M. R., Barker, G. J., Greenwood, R., & Duncan, J. S. (2001). Diffusion imaging shows abnormalities after blunt head trauma when conventional magnetic resonance imaging is normal. *Journal of Neurology, Neurosurgery, & Psychiatry*, 70, 530-533.
- Salmond, C. H., Menon, D. K., Chatfield, D. A., William, G. B., Pena, A., Sahakian, B. J., et al. (2006). Diffusion tensor imaging in chronic head injury survivors: correlations with learning and memory indices. *NeuroImage*, 29, 117-124.
- Sidaros, A., Engberg, A. W., Sidaros, K., Liptrot, M. G., Herning, M., Petersen, P., et al. (2008). Diffusion tensor imaging during recovery from severe traumatic brain injury and relation to clinical outcome: a longitudinal study. *Brain*, 131, 559-572.
- Sidaros, A., Skimminge, A., Liptrot, M. G., Sidaros, K., Engberg, A. W., Herning, M., et al. (2009). Long-term global and regional brain volume changes following severe traumatic brain injury: a longitudinal study with clinical correlates. *NeuroImage*, 44(1), 1-8.
- Sled, J. G., Zijdenbos, A. P., & Evans, A. C. (1998). A nonparametric method for automatic correction of intensity nonuniformity in MRI data. *IEEE Transactions on Medical Imaging*, 17, 87-97.
- Smith, D. H., Meaney, D. F., & Shull, W. H. (2003). Diffuse axonal injury in head trauma. *Journal of Head Trauma Rehabilitation*, 18(4), 307-316.
- Tanriverdi, T., Olivier, A., Poulin, N., Andermann, F., & Dubeau, F. (2009). Long-term seizure outcome after corpus callosotomy: A retrospective analysis of 95 patients. *Journal of Neurosurgery*, 110(2), 332-342.

- Taylor, H. G. (2004). Research on outcomes of pediatric traumatic brain injury: current advances and future directions. *Developmental Neuropsychology*, 25, 199-225.
- Teasdale, G., & Jennett, B. (1974). Assessment of coma and impaired consciousness. A practical scale. *Lancet*, 13(7872), 81-84.
- Thurman, D. J., Coronado, V., & Selassie, A. (2007). The epidemiology of TBI: implications for public health. In N. D. Zasler, D. I. Katz & R. D. Zafonte (Eds.), *Brain Injury Medicine*. New York: Demos Medical Publishing, LLC.
- Tomaiuolo, F., Carlesimo, G. A., Paola, M. D., Petrides, M., Fera, F., Bonanni, R., et al. (2004). Gross morphology and morphometric sequelae in the hippocampus, fornix, and corpus callosum of patients with severe non-missile traumatic brain injury without macroscopically detectable lesions: a T1 weighted MRI study. *Journal of Neurology, Neurosurgery, and Psychiatry*, 131, 1314-1322.
- Turken, A. U., Whitfield-Gabrieli, S., Bammer, R., Baldo, J. V., Dronkers, N. F., & Gabrieli, J. D. E. (2008). Cognitive processing speed and the structure of white matter pathways: convergent evidence from normal variation and lesion studies. *NeuroImage*, 42, 1032-1044.
- van der Zijden, J. P., van der Toorn, A., van der Marel, K., & Dijkhuizen, R. M. (2008). Longitudinal in vivo MRI of alterations in perilesional tissue after transient ischemic stroke in rats. *Experimental Neurology*, 212(1), 207-212.
- Wang, J., Bakhadirov, K., Devous, M. D., Adbdi, H., & McColl, R. (2008). Diffusion tensor tractography of traumatic diffuse axonal injury. *Arch Neurol*, 65(5), 619-626.
- Wang, S., Wu, E. X., Qiu, D., Leung, L. H., Lau, H. F., & Khong, P. L. (2009). Longitudinal diffusion tensor magnetic resonance imaging study of radiation-induced white matter

- damage in a rat model. *Cancer Research*, 69(3), 1190-1198.
- Wilde, E. A., Chu, Z., Bigler, E. D., Hunter, J. V., Fearing, M. A., Hanten, G. R., et al. (2006). Diffusion tensor imaging in the corpus callosum in children after moderate to severe traumatic brain injury. *Journal of Neurotrauma*, 23(10), 1412-1426.
- Wilde, E. A., McCauley, S. R., Hunter, J. V., Bigler, E. D., Chu, Z., Wang, J., et al. (2008). Diffusion tensor imaging of acute mild traumatic brain injury in adolescents. *Neurology*, 70, 948-955.
- Wu, T. C., Wilde, E. A., Bigler, E. D., Yallampalli, R., McCauley, S. R., Troyanskaya, M., et al. (2010). Evaluating the relationship between memory functioning and cingulum bundles in acute mild traumatic brain injury using diffusion tensor imaging. *Journal of Neurotrauma*, 27(2), 303-307.
- Xu, J., Rasmussen, I., Lagopoulos, J., & Haberg, A. (2007). Diffuse axonal injury in severe traumatic brain injury visualized using high-resolution diffusion tensor imaging. *Journal of Neurotrauma*, 24(5), 753-765.
- Yamada, K., Sakai, K., Akazawa, K., Yuen, S., & T., N. (2009). MR tractography: A review of its clinical applications. *Magnetic Resonance in Medical Science*, 8(4), 165-174.
- Yeates, K. O., Taylor, H. G., Drotar, D., Wade, S. L., Klein, S., Stancin, T., et al. (1997). Preinjury family environment as a determinant of recovery from traumatic brain injury in school-age children. *Journal of the International Neuropsychological Society*, 3(6), 617-630.
- Yuan, W., Holland, S. K., Schmithorst, V. J., Walz, N. C., Cecil, K. M., Jones, B. V., et al. (2007). Diffusion tensor MR imaging reveals persistent white matter alteration after traumatic brain injury experienced during early childhood. *American Journal of*

Neuroradiology, 28, 1919-1925.

Zhang, L., Thomas, K. M., Davidson, M. C., Casey, B. J., Heier, L. A., & Ulug, A. M.
(2005). MR quantitation of volume and diffusion changes in the developing brain.
American Journal of Neuroradiology, 26(1), 45-49.